



OFFICE OF THE CORONER Room 241 Hall Of Justice San Rafael, California 94903 ROBERT T. DOYLE			Coroner's Report In The Matter Of The Death Of: ROBIN MCLAURIN WILLIAMS			1. Case Number : 14-173	
2. Date Of Report 11/05/2014		3. Report Time 0800 HOURS		4. Date Of Death FND 08/11/2014		5. Time Of Death 1202 HOURS	
6. Sex MALE	7. Race CAUCASIA	8. Hair BROWN	9. Eyes BLUE	10. Age 63	11. Birth Date 07/21/1951	12. Nativity --	13. Citizenship USA
I. Personal Data	14. Aliases --						
	15. Street Address [REDACTED]			16. City [REDACTED]	17. County [REDACTED]	18. State CA	
	19. Soc. Security # --	20. Occupation ACTOR			21. Employer --		
II. Next Of Kin	<input checked="" type="checkbox"/> 22. Spouse's Name (Maiden Name) SUSAN WILLIAMS- WIFE	23. Address [REDACTED]			24. Phone [REDACTED]		
	<input type="checkbox"/> 25. Next Of Kin Name	26. Address			27. Phone		
	<input type="checkbox"/> 28. Next Of Kin Name	29. Address			30. Phone		
	<input checked="" type="checkbox"/> Family At Scene	31. Marital Status MARRIED	32. Notification By SPOUSE PRESENT, CONFIRMED BY K2		33. Time ~1210 HOUR	34. Date 08/11/2014	
III. Place Of Death	35. Death Pronounced By MEDIC 10, MARIN COUNTY FIRE		36. Place Of Death SINGLE FAMILY DWELLING				
	[REDACTED]			38. City TIBURON	39. City Limits NO		
	40. Mortuary / Location Remains Moved To NAPA COUNTY SHERIFF- CORONER FACILITY			41. Remains Moved By Order Of - Name & Relationship D. HARRIS, #K2			
IV. Dispo- sition Of Remains	42. Name Of Funeral Director MONTE'S CHAPEL OF THE HILLS			[REDACTED]			
	44. Disposition Of Remains CREMATION	45. Location Of Remains				46. Date	
V. Injury Data	47. Date 08/--/2014	48. Time UNKNOWN	49. Type Of Premises Or Facility OWN RESIDENCE				
	[REDACTED]			[REDACTED]			
	<input type="checkbox"/> Occured While Working	51. How Did Injury Occur					
52. Results Of Toxicology MIRTAZAPINE= 40 NG/ML; DESMETHYLMIRTAZAPINE= POSITIVE; CAFFEINE= POSITIVE; THEOBROMINE= POSITIVE; L-DOPHA= POSITIVE (APPROX. 0.31 MCG/ML); CARBIDOPA= NOT REPORTED							
53. Medical Cause Of Death ASPHYXIA; HANGING							
54. Other Significant Findings N/A							
<div style="text-align: center;">  <p>DATE: 11-5-14 RETURNED TO: [REDACTED] BY: [REDACTED] MARIN COUNTY CORONER'S OFFICE CORONER: KEITH BOYD</p> </div>							
Coroner's Verdict							
				ROBIN MCLAURIN WILLIAMS		Died	
Due To Or As A Consequence Of							
				SUICIDE		LT. KEITH BOYD <i>MB</i>	
Verdict Date : 11/05/2014				Coroner: ASST. CHIEF DEPUTY CORONER			

OFFICE OF THE CORONER Room 241 Hall Of Justice San Rafael, California 94903 ROBERT T. DOYLE			Coroner's Report In The Matter Of The Death Of: ROBIN MCLAURIN WILLIAMS			1. Case Number : 14-173	
2. Date Of Report 11/05/2014		3. Report Time 0800 HOURS					
4. Date Of Death FND 08/11/2014		5. Time Of Death 1202 HOURS					
6. Sex MALE	7. Race CAUCASIA	8. Hair BROWN	9. Eyes BLUE	10. Age 63	11. Birth Date 07/24/1951	12. Nativity ---	13. Citizenship USA
I. Personal Data	14. Aliases ---						
	15. Street Address [REDACTED]			16. City [REDACTED]	17. County [REDACTED]	18. State CA	
	19. Soc. Security # --	20. Occupation ACTOR			21. Employer --		
II. Next Of Kin	<input checked="" type="checkbox"/> 22. Spouse's Name (Maiden Name) SUSAN WILLIAMS- WIFE	23. Address [REDACTED]			24. Phone [REDACTED]		
	<input type="checkbox"/> 25. Next Of Kin Name	26. Address			27. Phone		
	<input type="checkbox"/> 28. Next Of Kin Name	29. Address			30. Phone		
	<input checked="" type="checkbox"/> Family At Scene	31. Marital Status MARRIED	32. Notification By SPOUSE PRESENT, CONFIRMED BY K2		33. Time ~1210 HOUR	34. Date 08/11/2014	
III. Place Of Death	35. Death Pronounced By MEDIC 10, MAREN COUNTY FIRE		36. Place Of Death SINGLE FAMILY DWELLING				
	[REDACTED]			38. City TIBURON	39. City Limits NO		
	40. Mortuary / Location Remains Moved To NAPA COUNTY SHERIFF- CORONER FACILITY			41. Remains Moved By Order Of- Name & Relationship D. HARRIS, #K2			
IV. Dispo- sition Of Remains	42. Name Of Funeral Director MONTE'S CHAPEL OF THE HILLS			[REDACTED]			
	44. Disposition Of Remains CREMATION		45. Location Of Remains		46. Date		
V. Injury Data	47. Date 08/--/2014	48. Time UNKNOWN	49. Type Of Premises Or Facility OWN RESIDENCE				
	[REDACTED]			[REDACTED]			
	<input type="checkbox"/> Occured While Working	51. How Did Injury Occur					
52. Results Of Toxicology MIRTAZAPINE= 40 NG/ML; DESMETHYLMIRTAZAPINE= POSITIVE; CAFFEINE= POSITIVE; THEOBROMINE= POSITIVE; LLEVODOPA= POSITIVE (APPROX. 0.31 MCG/ML); CARBIDOPA= NOT REPORTED							
53. Medical Cause Of Death ASPHYXIA; HANGING							
54. Other Significant Findings N/A							
<div style="text-align: right;">  <p> Date: <u>11-5-14</u> Relinquished to: <u>ASPL</u> By: <u>ASPL</u> MARIN COUNTY SHERIFF-CORONER CORONER'S OFFICE </p> </div>							
Coroner's Verdict							
				ROBIN MCLAURIN WILLIAMS		Died	
Due To Or As A Consequence Of							
Verdict Date : 11/05/2014				SUICIDE		LT, KEITH BOYD <i>KB</i> Coroner ASST. CHIEF DEPUTY CORONER	

SHERIFF'S OFFICE CORONER DIVISION COUNTY OF MARIN 1600 Los Gatos Dr. #205 SAN RAFAEL, CALIFORNIA 94903 (415) 473-6043 / (415) 473-6048 fax		CORONER INVESTIGATIVE REPORT In The Matter Of The Death Of;				CASE NO. CR14-173		
		{ Robin McLaurin WILLIAMS }				DATE OF REPORT 10.29.2014	TIME 1500 hours	
						DATE OF DEATH Found: 08.11.2014	TIME 1202 hours	
I.	SEX	COLOR OR RACE		ALIAS		CITIZENSHIP		
	M	Caucasian		--		USA		
	PHYSICAL DESCRIPTION				HAIR	EYES	HEIGHT	
	Superficial cuts to left wrist				BRN	BLU	5'08"	
Data	ADDRESS-STREET AND CITY				WEIGHT	AGE	BIRTHDATE	
	[REDACTED]				166lbs	63	07.21.1951	
	SOCIAL SECURITY NO.				OCCUPATION	EMPLOYER		
--				Actor	--			
II.	Next of Kin	N	RELATIONSHIP	NAME (MAIDEN NAME OF WIFE)	ADDRESS		PHONE	
		O	X Spouse	Susan Williams	[REDACTED]		[REDACTED]	
		T	--	--	--		--	
		F	--	--	--		--	
	E	X	NOK @ SCENE	NOTIFICATION MADE BY		TIME	DATE	
D	X	Yes	Spouse present shortly after medics pronounced. Confirmed by D. Harris, #K2		~1210	08.11.2014		
III.	DEATH PRONOUNCED BY			PLACE OF DEATH (FACILITY OR TYPE OF PREMISES)				
	Medic 10, Marin County Fire			Single Family Dwelling				
	ADDRESS			CITY		IN CITY LIMITS		
Place of Death	95 Saint Thomas Way			Tiburon, 94920		No		
	REMAINS REMOVED TO			ON ORDER OF-NAME AND RELATIONSHIP				
Napa County Sheriff - Coroner Facility			D. Harris, #K2					
IV.	PLACE OF INJURY			DATE OF INJURY		INDUSTRIAL	HOUR	
	Own Residence			08/--/2014		N/A	UNK	
V.	SYNOPSIS OF INJURY/DEATH							
	63-year-old male with a history of [REDACTED] was found deceased secondary to an apparent hanging in a locked bedroom in his residence. The subject displayed signs of rigor and lividity when found; therefore no resuscitative efforts were attempted. All medical history was initially supplied on scene by the subject's spouse, which was later confirmed by Coroner Division personnel upon receipt of medical records from the subject's primary medical doctor.							
	PAST MEDICAL HX							
	[REDACTED]							
Autopsy Info	CURRENT MEDICAL HX			CONTROLLED SUBSTANCE DIVISION FORBIDDEN BY LAW				
	Same							
	LAB WORK REQUESTED			Date: 11-5-14 Requested to: MEDIC #566				
	To be determined at Coroner Division triage							
	RX AVAILABLE			[REDACTED]				
Other Agency	REGULAR PHYSICIAN			CASE NO.				
	Dr. [REDACTED]			SO14-4622				
Agency	OTHER AGENCY			WITNESSES - NAME				
	Marin County Sheriff's Office			ADDRESS		PHONE		
			MCSO		473.7234			

01 **D. Harris** **K2** APPROVED BY: **LT. KEITH BOYD** *WAY 11-5-14*
INVESTIGATOR **ASST. CHIEF DEPUTY CORONER**

SHERIFF'S OFFICE CORONER DIVISION COUNTY OF MARIN 1600 Los Gatos Dr. #205 SAN RAFAEL, CALIFORNIA 94903 (415) 473-6043 / (415) 473-6048 fax	CASE NO.	CR14-173
	DATE OF DEATH	Found: 08.11.2014
DATE OF THIS REPORT	NAME OF DECEASED	REPORT BY
10.29.2014	Robin McLaurin WILLIAMS	D. Harris, #K2

MEDICAL HISTORY / SUMMARY / RX:

63-year-old male with a history of [REDACTED] was found deceased secondary to an apparent hanging in a locked bedroom in his residence. The subject displayed signs of rigor and lividity when found; therefore no resuscitative efforts were attempted. All medical history was initially supplied on scene by the subject's spouse, which was later confirmed by Coroner Division personnel upon receipt of medical records from the subject's primary medical doctor.

Hx: [REDACTED]

Rx: [REDACTED]

REPORTING PARTY INITIAL STATEMENT:

About 1300 hours, 08.11.2014, I was notified of the death of Robin M. Williams by Lt. Keith Boyd of the Marin County Sheriff's Office (MCSO) Coroner Division, and instructed to proceed to the scene to initiate a Coroner's investigation. The scene was located at a residence in unincorporated Tiburon at 95 Saint Thomas Way.

About 1333 hours, I arrived on scene and met with Sgt. K. Frey, Deputy J. Pence, Detective S. Buer, Detective Sgt. M. Hale and Lt. K. Boyd, at which time I received a briefing from Deputy Pence. Deputy Pence provided the following information:

The subject was a 63-year-old male who resided at [REDACTED] with his spouse, Susan Williams, and her teenage children. His prior medical history reportedly included depression, Parkinson's disease, and a recent increase in paranoia. He was last seen alive by his spouse, Susan Williams, at about 2230 hours the prior evening, at which time Susan retired to bed in a bedroom. The subject had reportedly been sleeping in his step-son's room, as the step-son was away with his father. The subject had been having a hard time sleeping and was restless due to his Parkinson's and anxiety issues, which is why he was sleeping in a separate bedroom. Earlier last evening the subject reportedly placed several wrist watches in a sock and gave them to [REDACTED] as he was reportedly worried about the watches and wanted [REDACTED] to keep them safe. This morning Susan awoke and noted the bedroom door where the subject had been sleeping was still closed. She assumed he was still sleeping. She left the house around 1030 hours this morning to run errands. [REDACTED] and [REDACTED] were at the subject's home this morning and [REDACTED] became concerned when the subject had not yet come out of his room. She slipped a note under the bedroom door, asking the subject if he was okay. [REDACTED] texted Susan at about 1142 hours, stating she was going to attempt to wake the subject up. [REDACTED] was in the process of retrieving a step stool to use in order to see into the window from the outside of the home. While he was doing this, [REDACTED] was able to use a paperclip to pop the push button lock on the bedroom door and gain access. [REDACTED] found the subject unresponsive on the floor near the bedroom closet and screamed for help. [REDACTED] responded to the bedroom and called 911. MCSO dispatch logged the 911 call at 1155 hours. [REDACTED] reported [REDACTED] told the dispatcher [REDACTED] At the dispatcher's direction, [REDACTED]

At this time [REDACTED] ceased efforts to remove the ligature. Medics from Southern Marin Fire, Medic 10, were on scene at 1200 hours and determined the subject's death at 1202 hours. No resuscitative efforts were attempted, as obvious signs of post mortem changes were present, including lividity and rigor. The subject was not moved and the scene was left as found. [REDACTED]

ORIGINAL DOCUMENT DUPLICATION OR REISSUANCE FORBIDDEN BY LAW n/c/14	
Date	MBOIA
Released to	ASDB
By	[REDACTED]
MARIN COUNTY SHERIFFS OFFICE CORONER DIVISION	

DEATH / INJURY SCENE INVESTIGATION:

I began my scene assessment at about 1354 hours.

The subject was located in a bedroom off a long hallway, which was on the opposite end of the home from the master bedroom. The room was fully furnished, with furniture items consisting of a large wood framed bunk bed, desk / chair, small refrigerator, 2-padded chairs (one flush to the bunk bed and the other against the wall adjacent to the entryway), wood shelved media cabinet with 3-padded stools slid beneath the cabinetry, and 3-large padded ottomans lined up beneath the bedroom window. The bedroom window was on the west side of the room and faced the street in front of the home. There were two closets on opposite ends of the room (northwest and southeast), each with a wood door. A full bathroom was connected to this bedroom. The room was in good order. The top and bottom bunk were fully dressed with bedding. The bedding on the top bunk was made. The bedding on the bottom bunk was crumpled and pulled down.

The subject was located adjacent to the exterior side of the closet door on the northwest side of the bedroom. He was in a seated position, facing west, and slightly leaning forward with a black nylon belt secured around his neck. The tongue slightly protruded forward and the tip was darkened. His right shoulder was in contact with the closet door, several inches below the doorknob. The lateral aspect of the right upper back was in contact with the wood molding on the closet door's frame. His left buttock was slightly elevated above the carpeted floor and the right buttock was in contact with the floor. His thighs were extended in front of his torso with both hands resting over the center of his thighs. His right leg was bent at the knee and crossed medially toward his left side. The left knee was flexed with the leg positioned laterally and away from the left side of his body. The opposite end of the belt around his neck was secured between the vertical side of the closed closet door and doorframe, positioned along the doorknob side of the door. The belt was fastened through a carbon slip lock style buckle and extended upward from the posterior side of the subject's neck and was fully taught. A folded white towel was looped over the belt, separating the belt from the skin along the anterior portion of his neck. The towel extended down to his waist, covering his chest and abdomen. There were no reflective devices or pornography anywhere near the subject's body.

The subject was wearing a black short-sleeve t-shirt, black jeans, black leather belt with a white metal belt buckle around the waist, and blue boxer-style underwear. His clothing was appropriately draped on his body. The t-shirt was untucked, but extended past the waist of his jeans. The sleeve over the subject's right shoulder was slightly pushed upward; it appeared the subject's weight was pressed against the doorframe and slid downward to his current position -- causing the shirt to bunch upward. The belt on his waist was appropriately threaded through the belt loops of his jeans and the metal buckle was fastened. His pant button and zipper were buttoned and fully zipped up. He was cool to palpation and rigor was appreciated in all extremities. Lividity was present in the distal upper extremities and visible over the lower abdomen and lower back. His face was suffused with a reddish tone above the ligature sight. Lividity blanched with firm pressure and rigor broke with moderate resistance. Both rigor and lividity patterns were consistent with the position the subject was in when I assessed him. A small amount of dark reddish tinted sputum was present from the nose and midline of the lower lip - the sputum extended down to the towel at the midline area over his upper chest. I noted a few very small punctate red marks in the lower eyelids. No sign of fluid was present in the ear canals.

The black nylon belt looped a single time around the anterior and lateral aspects of the neck and angled upward along the posterolateral aspects. The carbon slip lock buckle of the belt was positioned right of midline over the right posterior parietal region. The long end of the belt was threaded once through the slip lock and extended upward and slightly to the subject's right, where the distal end of the belt was wedged between the vertical aspect of the closed closet door and doorframe. The point below where the buckle was secured formed an inverted V pattern on the nylon belt strap. There was no sign of a furrow mark or abrasions on the neck or scalp in the void areas beneath this inverted V pattern over the posterior neck. The head hair beneath the buckle was pulled to the right and a slight reddened area on the scalp just above and to the left of the buckle was noted. The nylon material of the belt was flush against the neck, with no twists in the material. The belt ran along the anterior aspects of the neck and was positioned just below the jaw line. The belt was a little over of an inch wide. A white terry cloth towel was folded lengthwise and had been draped over the belt, creating a barrier between the skin and the belt along the anterior and right anterolateral aspects of the neck. I slightly manipulated the belt and towel in order to visualize the skin beneath. I noted signs of furrow marks on the neck beneath the towel and belt, which appeared consistent with the size and shape of the ligature. I did not fully visualize the neck, as I left the ligature and towel in place in for the Coroner's pathologist to examine them as found.

The height from the floor to the buckle positioned over the subject's posterior head was about 33". The distal end of the belt was wedged between the vertical aspect of the door and doorframe, about 61" from the floor. I could visualize the end of the nylon belt in the space between the door and doorframe, with the distal end of the belt positioned upward. The distance between the fastened buckle and the point where the belt was wedged in the doorframe was about 28". The distance from the top of the subject's head to the floor was about 36". I did not measure the length of the material looped around the neck, as the ligature was left in place for transport to the morgue. The c-spine appeared slightly elongated.

DUPLICATION OR REISSUANCE IS FORBIDDEN BY LAW	
Date	11/5/14
Released to	MOIA
By	ASOC
MARION COUNTY SHERIFFS OFFICE CORONER DIVISION	

I attempted to open the closet door and noted the doorknob easily turned, but the door did not immediately open. I had to shove the inward opening door open with a slight amount of force by pushing my shoulder into it. The nylon belt immediately dropped from the doorframe upon opening the door.

The walk-in closet contained neatly hung clothing, and multiple pairs of shoes stacked on wooden shelving units. A built-in row of belt hooks was part of the clothing / shelving unit in the closet. The belt hook rack held multiple leather and nylon belts.

The interior aspects of the closet doorframe were painted white and I saw no evidence of scratches, impressions or other marks on the paint over this portion of the doorframe. The portion of the door that runs flush to the doorframe had some scratches and markings in the paint. The markings and scratches appeared to run in a downward direction and slightly diagonal, angled toward the exterior side of the door. The markings started at about 68" above the floor. The highest mark measured about 1/2" in length. The next mark started about 64" above the floor and ran downward about 2". The final mark started at about 61" above the floor and ended at about 59" above the floor. The top of the final marking, 61", was the same height the distal end of the belt was found at prior to opening the door. The markings and their angles in the paint appeared consistent with the distal end of the belt having started at a higher position, subsequently slipping down the doorframe secondary to the subject's bodyweight.

I eased the subject to the floor and noted the sound of air expelling from the subject's mouth upon releasing him from the ligature. I saw no signs of trauma to the face, chest, abdomen, back or legs. Several superficial vertical and horizontal cuts were seen over the inner aspect of the left wrist; these wounds had a scant amount of blood present. No obvious signs of trauma or blood were seen over the palms or tops of the hands. The fingernails were trimmed and no signs of breakage were noted on the fingernails. I saw no evidence of blood on the carpet or door near the subject's body. A grouping of impressions was visible in the skin over the right upper-lateral aspect of the subject's back. These impressions were consistent with the shape of the wood molding on the doorframe the subject had been resting against prior to being released from the ligature. Some skin sloughing was present over the proximal end of the impression marks. The skin appeared to have been pushed in an upward direction, consistent with the body having slid down the wood molding.

I searched the subject's pockets and removed an iPhone in a battery charging cover, and a black cleaning cloth in the left front pant pocket. The right pocket held loose change, a few dollars in cash (folded and secured with a paperclip), keys and a car FOB. A wallet was also removed from the pants, which contained miscellaneous papers and bunk cards. The subject was not wearing a wrist watch or ring.

A padded chair was sitting flush against the bunk bed and held a few personal items on the seating portion of the chair: iPad with a red padded cover; nylon belt; closed pocket knife, with the following inscription "Presented By [REDACTED] closed bottle of Quetiapine (Seroquel); and single closed push pack dose of Mirtazapine (45mg). On the floor, along the west side of the chair, was a black pair of tennis shoes. Inside the right shoe was a pair of black socks. Inside the left shoe was a black hard case; this case appeared to belong to the pocket knife found on the chair, as the same inscription on the knife was also printed on the inside cover of the case.

I opened the locking blade of the knife found on the chair and immediately noted apparent dried blood on both sides of the blade's edges. I took digital photos of the both sides of the knife, with scale, and closed the blade. The non-serrated blade was 3" long. Smudge marks and suspected fingerprint ridge patterns were noted on the blade.

As noted above, the medication found on the chair in the bedroom included a single dose of Mirtazapine 45mg and a bottle of Quetiapine. The Quetiapine was prescribed by [REDACTED]. It was filled with 30-tabs on 08.04.14, with directions to take 1 tablet daily as needed. 22-tablets were still in the bottle.

The cell phone recovered from the subject's pant pocket did not hold a charge and would not turn on. I charged the phone while on scene and the subject's spouse provided me with the passcode. A search of the cell phone's call logs, texts, e-mails, notes, photos, videos and web browser revealed nothing to suggest suicidal ideation or that any messages of suicidal intent had been sent to anyone. Multiple alarm reminders were on the calendar, all set to remind the subject when to take medications. The last outgoing phone call was to the subject's spouse, dated 08.10.14 at 1908 hours. This call lasted 38-seconds. Susan later told me she briefly communicated with the subject last night when he reported he was picking up some magazines for her at the book store. She said he physically handed her the magazines upon returning home. Prior to this call, a call was made from the subject's phone to [REDACTED] on 08.10.14 at 1853 hours. [REDACTED] later reported to me this call was in relation to the subject dropping off the wrist watches at [REDACTED] home.

I searched the contents of the iPad found on the chair next the bunk bed. The web browser had several tabs open to websites discussing medications, including Lyrica and propranolol. There was also a webpage open from a Google search for [REDACTED]. I found nothing on the contents of the iPad consistent with suicidal ideation.

COPIES FOR	
DUPLICATION FOR REISSUANCE	
FORBIDDEN BY LAW	
Date	11-5-14
Released to	MEDIA
By	ASG
ALABAMA COUNTY SHERIFFS OFFICE	
CORONER DIVISION	

I searched the bathroom attached to the bedroom the subject was found in. There was a damp white washcloth on the bathroom sink's counter. The washcloth had a reddish substance on it, which appeared consistent with diluted fluid - possibly blood. There was no sign of blood anywhere else in the bathroom. An empty can of Ginger Ale was on the sink's counter. I smelled the contents of the can and it smelled consistent with soda. The lid on the commode was up and the seat was down. The commode contained yellowish fluid and toilet paper. I found no medications or anything else of significance in the bathroom.

The rest of the bedroom contained property consistent with belonging to a teenager, such as school supplies and video game accessories. The bedroom and bathroom windows were covered with drop down shades. The windows faced the street and were both locked.

I asked the subject's spouse if Mr. Williams used a personal computer. She showed me a laptop computer in the kitchen / dining area of the home and stated it belonged to the subject. Both the spouse and [REDACTED] told me the subject rarely used the computer and most of his correspondence was done on the phone or in writing. Mrs. Williams allowed me to search the contents of the laptop. I found nothing of significance to this case upon reviewing the computer.

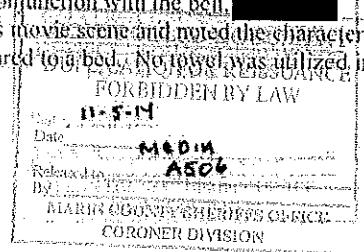
I spoke with Mrs. Williams and [REDACTED]. Both were very emotional and highly cooperative and very candid. I summarized the following after interviewing them:

The subject reportedly suffered sporadically from depression for most of his adult life. He had a prior history of alcohol and drug abuse, but had reportedly been sober for several years. He also struggled with anxiety and paranoia in the past, but more so over the last year. Despite his long history of depression, he had no known history of suicidal ideation or behavior. In addition to his recent uptick in depression, he was recently diagnosed with early Parkinson's disease. In late June and part of July, 2014, the subject checked into the Lodge at Hazelton, located in Minnesota, which is a retreat associated with a drug / alcohol rehabilitation center. Mrs. Williams stated he did not check in for drug or alcohol abuse, but at the direction of [REDACTED] - who suggested the retreat to aid in essentially rejuvenating the principals of the 12-step program. The hope was the subject would apply the principles in facets of his life he was having struggles with. The subject had been having a difficult time sleeping and would sometimes move around a lot in bed or talk loudly in his sleep, which is why he was sleeping in a separate bedroom from Mrs. Williams. There had been no recent physical or verbal arguments between the subject and his spouse. Yesterday the subject reportedly became concerned about several of his wrist watches, which Mrs. Williams and [REDACTED] attributed to the typical signs of paranoia he had been displaying. The subject secured several watches in a sock and drove them to [REDACTED] house. [REDACTED] received the watches and said the subject asked [REDACTED] to take care of them. The subject was at [REDACTED] house sometime between 1900 and 1930 hours, 08.10.14. Mrs. Williams said the subject seemed okay when he arrived home last night. She recalled he was in out of their bedroom several times late last night and rummaged through their bedroom closet. She said he grabbed his iPad and she recalled thinking it was good thing he grabbed it, because she assumed he was in a good mood and was going to take time to do some reading; he hadn't read or watched TV in about 6-months. He left the bedroom the final time around 2230 hours. At that time she recalled he was wearing a black t-shirt and blue boxers and she described his demeanor as excited.

I asked Mrs. Williams about the knife found in the room and to whom it belonged to. She said the subject received multiple gifts from military figures when entertaining troops overseas. The subject had a collection of knives he'd receive over the years - she was certain the knife belonged to the subject. While on the topic on the knife I asked if the subject was right hand or left hand dominant. Mrs. Williams stated the subject was right handed.

[REDACTED] was very familiar with the subject's personal issues and medical care. Mrs. Williams said [REDACTED] and she had no issues with [REDACTED] being present for the interview process, as [REDACTED] would likely be able to assist with contacts for the subject's medical care practitioners, [REDACTED] and Mrs. Williams provided me with the names and contact information for the subject's primary doctor, [REDACTED] and his psychiatrist, [REDACTED].

I asked Mrs. Williams if the subject had ever mentioned suicide as a solution to a significant health issue. She said it's not a discussion they ever had and he didn't mention anything about suicide following his Parkinson's diagnosis. I asked if she was aware of any prior research he'd done on the subject of suicide or hanging specifically. I also asked [REDACTED] and Mrs. Williams if anyone removed or moved anything at all from the scene; they stated nothing was moved or taken prior to arrival of the police and fire department. [REDACTED] interjected and asked if I was referring to the use of the towel the subject used with the belt in this case. I then frankly asked if the subject had any history of autoerotic asphyxia. Mrs. Williams stated he did not. [REDACTED] then stated the subject worked on a movie several years ago in which a character who played Mr. Williams' son died in a scene, wherein the son accidentally died secondary to autoerotic asphyxiation. [REDACTED] said the scene was very difficult and emotional for Mr. Williams. [REDACTED] said he may have gleaned some information from the scene in regard to using the towel in conjunction with the belt. [REDACTED] thought the subject possibly used to towel in order to avoid pain. Of note, I later viewed this movie scene and noted the character that died was found seated on the floor, leaning forward with a ligature around the neck secured to a bed. No towel was utilized in the movie scene.



provided me with a daily pill dispenser box, marked Sunday thru Saturday. said just filled the box with the subject's prescription medications the prior day. and Mrs. Williams said the subject had complained in the past about not liking the way some of his medications made him feel, but they believed he was taking them as prescribed. The medications were still in each day's slot. I collected the box and the pill bottles they were dispensed from. The medications included: Mirtazapine; Rapaflo; Carbidopa-Levodopa; Quetiapine; Finasteride; and Vitamin D. Medication not in the pill box included Lansoprazole (prescribed in 2011) and Amoxicillin (for pre-dental appt.).

Prior to clearing the scene, I had the subject secured on a gurney and covered him with a blanket from the neck down. I allowed Mrs. Williams an opportunity to view the subject's remains. I stayed in the room with Mrs. Williams, along with the Sheriff's Chaplain, whom Mrs. Williams invited into the room in order to pray with her. I supervised the viewing and it concluded without incident.

Upon returning to the Coroner Division, I called and spoke with Dr. as reported by Mrs. Williams and

[REDACTED] Dr.
[REDACTED] Dr.
[REDACTED] Dr.
[REDACTED] Dr.

I obtained a copy of the subject's medical records from Dr. Upon review I found the information Dr. verbally relayed me to be consistent with the content of the records.
[REDACTED]


I also requested and received medical records for the subject from Marin General Hospital, Cardiovascular Associates of Marin and the Cleveland Clinic. All records were forwarded to the Coroner Division's Chief Forensic Pathologist for review.

I called and spoke with Dr. [REDACTED]

Of note, MCSO detectives were on this scene investigation with me and upon the conclusion of the scene investigation and interviews with the subject's spouse no indication of foul play was suspected.

MODE OF DECEDENT IDENTIFICATION:

A initially identified the subject as Robin Williams. I later confirmed the subject's identification by comparing a post mortem inked right thumbprint to the print on file with the subject's government issued photo identification: CA Driver's License Robin McLaurin Williams (DOB 07.21.1951)



PROPERTY & EVIDENCE COLLECTION / RELEASE:

I took several digital photos of the scene and of the subject's remains. All photos were retained at the Coroner Division.

I removed the following items from the subject's pant pockets: iPhone with charging case (battery expended); black cleaning cloth; wallet containing multiple credit cards and business cards; car key with FOB on a leather rope with a white metal skull charm; cash folded in a paperclip; loose change.

The cell phone's call logs, notes, text logs, e-mail, photos and internet web browser were reviewed on scene - all items of property were then released to the subject's spouse prior to clearing the scene.

The following items were collected as evidence by Detective Scott Buer (MCSO): A pocket knife and its case found in the bedroom, and a damp white washcloth with reddish stains found in the bathroom.

The belt and towel secured around the subject's neck was left in place during transport from the scene to the morgue. These items were collected at autopsy by Coroner Investigator K. Advincula and released to Detective Buer with the investigative division of the Marin County Sheriff's Office on 08.12.2014.

On 08.12.2014, full body x-rays were obtained while the subject was at the Napa County morgue facility. Copies of the x-rays were retained at the Coroner Division. The Coroner Division's pathologist found no obvious fractures upon review of the x-rays.

I rolled a full set of inked fingerprints from the subject. The print cards were retained with the case file.

On 08.20.2014, I signed out the above-mentioned pocket knife from Detective Leonard (MCSO), whom retrieved the knife from MCSO evidence; MCSO Evidence Item #140005201 #5. I prepared the knife, along with a single purple top of post mortem blood drawn from this subject, for shipment to the NMS DNA lab for DNA comparison on behalf of MCSO Investigations Division.

On 08.29.2014, the knife was returned from the NMS DNA lab. The knife was printed by Detective Leonard (MCSO), who reported the fingerprints on the knife were inconclusive.

On 10.17.2014, NMS labs confirmed the suspected dried red blood on the blade was in fact human blood. Subsequent DNA analysis of this blood confirmed it was the subject's blood.

FUNERAL HOME / TRANSPORT:


I secured an ID bracelet to the subject's ankle and placed his remains in a white body pouch; the pouch was sealed with lock #030873. The subject was then transported by the Coroner Division's transport service to the Napa County Sheriff Coroner's facility for increased security - pending further examination / case review by the Coroner Division's pathologist.

On 08.12.2014, at the conclusion of the autopsy, the subject was secured in a body pouch, which was resealed with lock #030830 by Coroner Investigator K. Advincula. The subject was then transported to Chapel of the Hills mortuary by the Coroner Division transport service, which was the mortuary of choice for the subject's spouse.

I accessed the subject's body pouch upon his return to Chapel of the Hills mortuary in order to roll a set of inked fingerprints. The above-mentioned lock, #030830, was still in place. I removed the lock to obtain the fingerprints and then re-sealed the pouch with lock #33015.

NEXT OF KIN CONTACT / SEARCH INVESTIGATION:

The subject's spouse, Susan Williams, was present on scene upon my arrival. I went over the Coroner Division's role in this case with her and discussed the possibilities of a forensic autopsy taking place. Mrs. Williams indicated she understood the reasoning for the Coroner's involvement and she voiced no objections or concerns. Mrs. Williams allowed [REDACTED] to be present during my interview with her. She said I could communicate either directly with [REDACTED] Susan, or provide information to [REDACTED] who would relay information to Susan.





CORONER DIVISION

Robert T. Doyle, Sheriff-Coroner
 Marin County Sheriff's Office
 1600 Los Gatos Drive Suite #205, San Rafael, CA 94903
 Phone: 415-473-6043 Fax: 415-473-6048


Evidence/Property Receipt

Case #: 14-172 Decedent: Williams, Robin Date: 8-11-14 Investigator: LaRocca #22

Item #	Description	Item #	Description
141	1x Metal Case for Forensic		
142	CA 94 [Redacted]		
/			
/			
/			
/			
/			
/			
/			
/			
/			

Chain of Custody

Item #	Description	Released or Returned To	Released or Received By	Date / Time
141	1x Metal Case for Forensic	Deputy [Redacted], [Redacted]		
142	CA 94 [Redacted]	CA DMV by Coroner Division - [Redacted]		





CORONER DIVISION

Robert T. Doyle, Sheriff-Coroner
 Marin County Sheriff's Office
 1600 Los Gatos Drive Suite #205, San Rafael, CA 94903
 Phone: 415-473-6043 Fax: 415-473-6048

Prescription Medication Inventory Sheet

Coroner Case Number: CR14-173
 Decedents Name: Williams, Robin
 Property Sheet Item Number: 1

Investigator: D. Harris, #K2
 Date of Death: found 08.11.2014

Name of Drug and Dosage	Number Prescribed	Number Remaining	Physician	Date Prescribed	Date Filled	Pharmacy	Where Located
Lansoprazole 30mg 1 PO QD	30	29	[REDACTED]	--	12.11.11	Walgreens	Mill Valley 380.8402
Rapaplo 8mg 1 PO QD	30	28	[REDACTED]	--	07.28.14
Linastende 5mg 1 PO QD	30	29	[REDACTED]	--	07.28.14
Amoxicillin 500mg 4 PO 1 hour prior to dental appointment	12	14	[REDACTED]	08.06.2014	08.06.2014	Rite Aide	Corte Madera 924.4557
Quetiapine 25mg 1 PO QD PRN	30	22	[REDACTED]	08.04.2014	08.04.2014
Carbidopa-l. evodopa 25-100 1 PO TID	90	47	[REDACTED]	07.25.2014	07.25.2014

CONTROLLED DOCUMENT
 DUPLICATION OR REISSUANCE
 IS FORBIDDEN BY LAW
 Date: 11-5-14
 Released to: MLOIA
 By: ASEV
 MARIN COUNTY SHERIFF'S OFFICE
 CORONER DIVISION

Prescription Meds Inventory 06/09/14

Mirtazapine 45mg dissolve 1 on tongue OJIS	30	21		--	07.30.2014	Walgreens	Mill Valley 380.8402
Vitamin D Loose Rx in daily pill dispenser	--	7		--	--	--	--

CONTROLLED DOCUMENT
 DUPLICATION OR REISSUANCE
 FORBIDDEN BY LAW
 Date: 11-6-14
 Released to: MEDIA
 By: ASPO
 MARICOUNTY SHERIFF'S OFFICE
 CORONER DIVISION

me



CORONER DIVISION

Robert T. Doyle, Sheriff-Coroner
 Marin County Sheriff's Office
 1600 Los Gatos Drive Suite #205, San Rafael, CA 94903
 Phone: 415-473-6043 Fax: 415-473-6048

Evidence/Property Receipt

Case #: CE14-173 Decedent: William R. Rubin Date: 8/12/14 Investigator: D. Harris
R. Adkins

Item #	Description	Item #	Description
KA1	White Towel	KA1	White Towel
KA2	Grey/Black Belt w/ Metal Buckle	KA2	Grey/Black Belt w/ Metal Buckle
KA3	Band: Brown Dressing	KA3	Band: Brown Dressing
KA4	White Towel	KA4	White Towel
KA5	White Towel	KA5	White Towel
KA6	White Towel	KA6	White Towel
KA7	White Towel	KA7	White Towel
KA8	White Towel	KA8	White Towel
KA9	White Towel	KA9	White Towel
KA10	White Towel	KA10	White Towel

Chain of Custody

Item #	Description	Released or Returned To	Released or Received By	Date/Time
KA1	White Towel		R. Adkins, # 101	8/12/14 @ 12:00
KA2	Belt		R. Adkins, # 101	8/12/14 @ 12:00

CONTROLLED DOCUMENT
 DUPLICATION OR REISSUANCE
 FORBIDDEN BY LAW
 Date: 11.5.14
 Released to: W401A
 By: RSEK
 MARIN COUNTY SHERIFF'S OFFICE
 CORONER DIVISION



CORONER DIVISION

Robert T. Doyle, Sheriff-Coroner
 Marin County Sheriff's Office
 1600 Los Gamos Drive Suite #205, San Rafael, CA 94903
 Phone: 415-473-6043 Fax: 415-473-6048

Evidence/Property Receipt

Case # 0214-173 Decedent: See, down Date: 8/20/14 Investigator: HARRIS

Item #	Description	Item #	Description
1	WOUNDS / LUNGS / BEER KATIE	1	
2		2	
3		3	
4		4	
5		5	
6		6	
7		7	
8		8	
9		9	
10		10	

Chain of Custody

Item #	Description	Released or Returned To	Released or Received By	Date / Time
1	WOUNDS / KNIFE	Exchange / Released	V. HARRIS	7/20/14 15:22
2	WOUNDS / KNIFE	Return to name listed	V. HARRIS & K.L.	8/20/14

CONTROLLED DOCUMENT
 DUPLICATION OR REISSUANCE
 FORBIDDEN BY LAW
 Date: 11-2-14
 Released to: MARIA
 By: ASOV
 MARIN COUNTY SHERIFF'S OFFICE
 CORONER DIVISION



CORONER DIVISION

Robert T. Doyle, Sheriff-Coroner
Marin County Sheriff's Office
1600 Los Gamos Drive, Suite 200, San Rafael, California 94903
Phone: 415-499-6043 Fax: 415-499-6048

AUTOPSY PROTOCOL

NAME OF DECEDENT: Robin McLaurin Williams

FILE NUMBER: CR14-173

DATE OF AUTOPSY: August 12, 2014

DIAGNOSES:


- I. Hanging, with:
 - A. Asphyxia, minutes.
 - B. Belt ligature encircling the neck.
 - C. Ligature mark with slight furrow of neck.
 - D. Congestion of the head, above application of ligature.
 - E. Red-brown postmortem dry artifact associated with ligature mark.
 - F. Anterior aspect of ligature mark at and above the level of thyroid cartilage (larynx).
 - G. Upward course of ligature mark to lateral aspects of neck.
 - H. Upward extension of ligature mark along left lateral neck to posterior neck.
 - I. Disappearance of left upper margin of ligature mark at mid-suboccipital neck.
 - J. Disappearance of left lower margin of ligature mark at left posterior neck.
 - K. Disappearance of ligature mark at lateral aspect of right side of neck.
 - L. Ligature abrasion, anterolateral aspect of right side of neck, small (1/4 inch).
 - M. Ligature abrasion, lateral aspect of left side of neck (3/4 inch).
 - N. Palpebral conjunctival petechiae, rare.
 - O. Absence of bulbar conjunctival hemorrhage.
 - P. Absence of strap muscle hemorrhage.
 - Q. Absence of injury to hyoid or cartilages of neck.
 - R. Absence of injury to cervical vertebrae.
 - S. Absence of prevertebral, posterior pharyngeal or periesophageal hemorrhage.
 - T. Protrusion and red-brown postmortem dry artifact of tongue.
 - U. Contusion of tongue (intraglossal).
 - V. Soft tissue hemorrhage, left medial supraclavicular, focal, small (3/4 inch).
 - W. Circumferential livor mortis, lower aspect of torso.
 - X. Circumferential livor mortis, lower extremities.
 - Y. Tardieu spots of the thighs, circumferential, associated with livor mortis.

- II. Incised wounds of left wrist, multiple, acute, small, superficial, with:
 - A. Absence of injury to major vessels or structures of the wrist.

- III. Healing abrasion, right arm, small (1/8 inch).

CONTROLLED DOCUMENT
DUPLICATION OR REISSUANCE FORBIDDEN BY LAW
Date <u>11-5-14</u>
Released to: <u>MEDIA</u>
By: <u>ASPC</u>
MARIN COUNTY SHERIFFS OFFICE
CORONER DIVISION

- IV. Hypertensive, atherosclerotic and valvular cardiovascular disease, with:
- A. Hypertrophy and dilation of the heart, marked (530 grams).
 - B. Pitting edema, lower extremities, moderate.
 - C. Arteriolonephrosclerosis, slight.
 - D. Atherosclerosis, aorta and branches, minimal.
 - E. Atherosclerosis, coronary arteries, slight.
 - F. History of aortic valve regurgitation, status post bioprosthetic aortic valve replacement, remote.
 - G. History of mitral valve regurgitation, status post mitral valve repair, remote.
 - H. History of reduced left ventricular ejection fraction.
 - I. History of atrial fibrillation.
 - J. History of palpitations.
 - K. Pulmonary congestion and edema, moderate.
- V. Neuropathologic diagnoses (see separate neuropathology report):
- A. Diffuse Lewy body dementia (DLBD, aka diffuse Lewy body disease), with:
 1. Alpha-synuclein proteinopathy, substantia nigra and ventral tegmental area, occipital cortex, insular cortex, temporal cortex, putamen and amygdala, microscopic.
 2. Reduced neuronal density, midbrain (substantia nigra and ventral tegmental area), microscopic.
 3. History of left upper extremity tremor, impairment of left hand movement, anxiety, depression, insomnia, paranoia and unspecified cognitive impairments, consistent with diffuse Lewy body dementia.
 4. Clinical diagnosis of Parkinson's disease, recent (November, 2013).
 5. Treatment with pramipexole and levodopa, recent.
 - B. Other contributing neurodegenerative features:
 1. Tauopathy, anterior hippocampus, temporal cortex, cerebral cortex, subcortical white matter, dorsal raphe nucleus in midbrain, microscopic.
 2. Astrogliosis, subcortical white matter, tegmentum of midbrain, and cerebellar white matter, microscopic.
 - C. Amyloid angiopathy, microscopic.
- VI. History of alcohol and substance abuse, with.
- A. Please refer to separate toxicology report.
 - B. Absence of alcohol or illicit drug, postmortem femoral blood sample.
 - C. Therapeutic concentration of levodopa, postmortem femoral blood sample.
 - D. Therapeutic concentration of mirtazapine, postmortem femoral blood sample.
 - E. Presence of caffeine and theobromine, postmortem femoral blood sample.
 - F. Absence of steatosis or fibrosis of the liver, gross and microscopic.
 - G. Absence of needle tracks or recent punctures, extremities.
- VII. Absence of skeletal injury.
- VIII. Appendectomy, remote.
- IX. Nodular hyperplasia of the prostate, with:
- A. Trabeculation of the urinary bladder.
 - B. Benign prostatic nodule, adjacent to bladder neck.



CAUSE OF DEATH: ASPHYXIA DUE TO HANGING

"I hereby certify that I, Joseph I. Cohen, M.D., Chief Forensic Pathologist of Marin County, have performed an autopsy on the body of Robin McLaurin Williams on the 12th day of August, 2014, commencing at 8:35 a.m. at the Coroner Division of the Napa County Sheriff-Coroner."

This examination was assisted by Coroner Forensic Technician Alex Torres and Coroner Investigator Kenneth Advincula of the Marin County Sheriff-Coroner, Coroner Division. The examination commenced by breaking a red body bag seal bearing the number 030873. Upon completion of the examination, a red body bag seal bearing the number 030830 is affixed to the body bag.

EXTERNAL EXAMINATION:

The decedent is received in a white body bag. The body is of a well-developed, well-nourished man whose appearance is consistent with the stated age of 63 years. The body length measures approximately 68 inches; the receiving weight is approximately 166 pounds.

The scalp hair is dark with moderate grey and measures up to approximately 2 inches in length. The irides appear blue and the conjunctivae are free of jaundice. Rare ocular petechial hemorrhages are described below. The oral cavity has natural teeth in good condition. There is a mustache and moderate beard stubble. The eyes, ears, nose and mouth are normally developed. The nasal septum is intact. The neck is symmetrical. The chest and abdomen are free of injury. A 9 inch, vertical, midline sternotomy scar is on the anterior chest. A 3½ inch, slightly obliquely oriented scar is on the right lower quadrant of the abdomen. A tattoo is on the left hip. The external genitalia are of a normal, circumcised, adult man. Injuries to the neck are described below. The back and buttocks are free of injury. There are no injuries to the perianal region. A collection of semisolid, slightly dry, green-brown stool are on the perianal area.

There are no apparent scars on the wrists (comment: injuries to the left wrist are described below). A ½ inch oblique scar is on the anterior aspect of the distal right forearm. The fingernails are of short to moderate length, and well-trimmed. There are no injuries to the hands or feet. There is moderate pitting edema of the legs. A red identification band encircles the left ankle, bearing the decedent's name and Coroner file number.

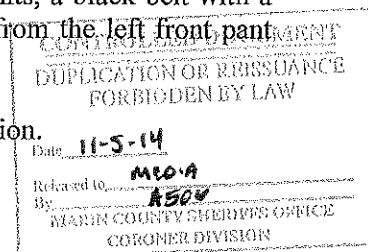
POSTMORTEM CHANGES: The decedent is received unembalmed and well preserved without signs of significant decomposition. Rigor mortis is moderate and symmetrical in the extremities. Livor mortis is moderate and blanches on the dorsal surfaces of the body, and the body is cool.

There is patchy, circumferential livor mortis over the mid and lower aspects of the torso, quite diffuse and more pronounced over the abdominopelvic region, and over the lower extremities. Tardieu spots are scattered over the anterior and posterior aspects of the thighs, on the inferior buttock regions, and on right lower quadrant of the abdomen (comment: Tardieu spots are generally more prominent on the right).

There is an obliquely oriented, oval shaped, slightly indented, 4 x 1 inch, multicolor (yellow-beige-green) patch of postmortem dry artifact on the lateral aspect of the right side of the torso.

CLOTHING: The body is clad in a black, short sleeved t-shirt, black denim pants, a black belt with a white metal buckle, and blue boxer type underwear. A lens cloth is recovered from the left front pant pocket.

THERAPEUTIC PROCEDURES: There is no evidence of therapeutic intervention.



INJURIES, EXTERNAL AND INTERNAL: A belt ligature, measuring approximately 40 inches in length, encircles the neck. The ligature is slightly loose, not tight around the neck. The buckle is positioned behind the head where it is secured to the belt, forming a ligature. A folded, white towel is in place, looped over the front of the ligature (comment: positioned between the skin of the anterior neck and the belt ligature) and resting on the anterior torso. There is moderate congestion of the head and neck, above the level of the ligature. A shallow, blanched, band like ligature furrow on the anterior and lateral aspects of the neck, associated with patchy, red-brown postmortem dry artifact, correlates with the position of the ligature. Dry artifact is more prominent on the inferior aspects of the ligature furrow. There are generally well defined upper and lower margins of the ligature mark, though the margins are less defined on the anterior neck. From the anterior neck, the mark extends obliquely upwards toward the sides of the neck. On the anterior midline, the width of the furrow reaches a maximum width of approximately 2 inches (comment: due to the presence of cloth between the skin of the neck and the ligature) and overlies the anterior neck at and above the level of the thyroid cartilage. The width of the ligature mark tapers to approximately 1 inch on the lateral aspect of the left side of the neck, and the mark terminates on the posterior neck (comment: the upper margin of the mark terminates on the mid-posterior neck, at mid-ear level; the lower margin terminates on the left posterior neck close to the midline, at the suboccipital level; the furrow disappears, blending with livor mortis toward the posterior neck where the ligature mark is reduced to slender, blanched, parallel margins). On the lateral aspect of the right side of the neck, the ligature mark disappears, blending into livor mortis. A small, ¼ inch, red-brown ligature abrasion is on the anterolateral aspect of the right side of the neck, and a ¾ inch, red-brown ligature abrasion is on the lateral aspect of the left side of the neck. A subtle ½ inch red-brown area of postmortem dry artifact is on the inferior margin of the ligature mark, on the anterior neck just to the left of midline.

The tongue protrudes slightly from the oral cavity and there is postmortem dry artifact of the tip of the tongue. There are rare, scattered palpebral conjunctival petechial hemorrhages (comment: several are identified); there are no bulbar conjunctival hemorrhages. There are no petechiae of the face or buccal mucosa. Subsequent dissection reveals absence of strap muscle hemorrhage, absence of injury to the hyoid or cartilages of the neck, and absence of injury to the cervical vertebrae. There is no prevertebral or posterior pharyngeal hemorrhage. There is an intraglossal contusion of the mid-distal tongue. A ¾ inch hemorrhage is in the soft tissue of left medial supraclavicular area.

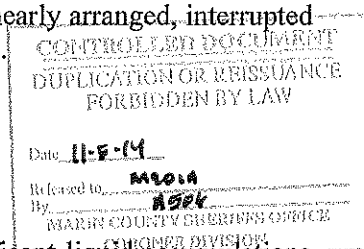
There are multiple (numbering approximately 10), small, 1/8 to ¼ inch, superficial, fresh, slightly oozing, incised wounds over a 1½ x 1½ inch area on the anterior aspect of the left wrist. The wounds are generally oriented in parallel and perpendicular fashion, and include several linearly arranged, interrupted wounds. Several of the wounds have a focal, purple-blue margin of ecchymosis.

A 1/8 inch healing abrasion is on the anteromedial aspect of the distal left arm.

INTERNAL EXAMINATION:

BODY CAVITIES: The organs are in their usual situs. There are no significant liquid accumulations within the body cavities. There are marked, diffuse pericardial adhesions (comment: consistent with remote cardiac surgery). There are no pleural adhesions. Slight, focal adhesions are in the right lower quadrant of the abdominal cavity (comment: consistent with remote appendectomy). The blood has a serous consistency.

HEAD: The scalp is atraumatic. There are no skull fractures, and there are no epidural, subdural or subarachnoid hemorrhages. The 1750 gm brain is symmetrical and has normal gyri and sulci. There are no acute or remote contusions of the brain. The leptomeninges are smooth, delicate and transparent, and the leptomeningeal vessels are normal. The arteries at the base of the brain are free of significant



atherosclerosis. The cranial nerves have normal distributions. The surfaces of the brainstem and cerebellum are unremarkable.

The cortical gray matter, subcortical and deep white matter, deep gray nuclei and ventricles are macroscopically unremarkable. There is no intracerebral hemorrhage. The cerebrospinal fluid is clear. Horizontal sections of the brainstem and cerebellum are unremarkable, except for moderate, relative pallor of the right substantia nigra. Representative sections of brain, brainstem and cerebellum are retained in formalin, and samples are submitted for routine microscopic and formal neuropathology evaluation.

NECK: Injuries to the neck were described above. The cervical vertebrae, hyoid, tracheal and laryngeal cartilages and paratracheal soft tissues are normal. The upper airway is not obstructed. Contusion of the tongue was noted above.

CARDIOVASCULAR SYSTEM: The aorta and branches have slight atherosclerosis. The venae cavae and pulmonary arteries have no thrombus or embolus.

The markedly dilated and enlarged, 530 gm heart has a normal distribution of right dominant coronary arteries. The epicardial vessels have slight narrowing by atherosclerosis with up to 10 – 15 % maximal narrowing of the major vessels. The left ventricle wall thickness measures 1.0 cm. A remotely replaced aortic valve is intact and free of thrombus. The mitral valve appears unremarkable (comment: there is a history of mitral valve repair). The tricuspid and pulmonic valves are free of thickening, vegetation or thrombus. The endocardial surfaces, chordae tendineae and papillary muscles are unremarkable.


RESPIRATORY SYSTEM: The right lung weighs 630 gm, and the left lung, 590 gm. The lungs are well inflated and the visceral pleural surfaces are smooth and glistening. The parenchyma is red and wet without consolidation. Slight to moderate quantities of frothy liquid and blood exude from the cut surfaces. The bronchi contain slight quantities of similar liquid. The vessels have no thrombus or embolus.

LIVER, GALLBLADDER, PANCREAS: The 2030 gm liver has a smooth, intact capsule. The parenchyma is red-brown. There is no macroscopically appreciable fatty change or fibrosis. The bile ducts are unremarkable. The gallbladder contains approximately 15 cc of dark green viscid bile without stones. The pancreas is uniformly tan-gray and has a normal lobular appearance.

HEMIC AND LYMPHATIC SYSTEMS: The 180 gm spleen has a smooth, intact capsule. The parenchyma is plum colored and moist with distinct follicles. There are no lymph node enlargements. The thymus is atrophic. The bone marrow of the ribs and clavicles is unremarkable.

GENTOURINARY SYSTEM: The kidneys weigh 180 gm each. The cortices are slightly finely granular and the parenchyma has demarcated corticomedullary junctions. The vessels are unremarkable, free of significant atherosclerosis. The calyces and pelves are empty, opening into ureters which maintain uniform caliber and open into a full urinary bladder containing approximately 300 cc of clear, yellow urine. The epithelial surfaces of the bladder display marked trabeculation.

The testes are examined, and they are unremarkable. The prostate is slightly enlarged with nodular grey-tan cut surfaces (comment: due to nodular hyperplasia). There is a firm, ½ inch prostatic nodule adjacent to the bladder neck.



ENDOCRINE SYSTEM: The pituitary is unremarkable. The thyroid is small and symmetrical with uniform, red-brown, glandular cut surfaces. The adrenal medullae are covered by thin, focally expanded, golden yellow cortices.

DIGESTIVE SYSTEM: The esophagus is unremarkable. The stomach contains 200 cc of partially digested food, including tentative pieces of light color meat and/or fruit or vegetable material. The gastric mucosa is free of ulcer or tumor, and displays normal appearing rugal folds. The pylorus is unremarkable. The small and large intestines are unremarkable, free of ulceration, wall thickening or tumor. The small intestine contains green-yellow chyme; the large intestine contains moderate quantities of green, semisolid stool admixed with occasional pieces of corn. The appendix is surgically absent.

MUSCULOSKELETAL SYSTEM: The musculature is well developed and normally distributed. There are no acute skeletal injuries.

SAMPLES RETAINED, SPECIAL STUDIES:

The following samples are retained for possible toxicological evaluation: Femoral blood, urine, vitreous, liver tissue, brain tissue, and gastric contents.

Tissue samples are collected and placed in formalin, and samples are submitted for routine histological and formal neuropathology evaluation.

Blood is retained in purple and red top tubes.

Full body radiographs are obtained prior to the examination. There are no acute skeletal injuries.

Photographs are obtained by Coroner Investigator Kenneth Advincula of the Marin County Sheriff-Coroner, Coroner Division.

The belt ligature and clothing are submitted to Coroner Investigator Kenneth Advincula.

MICROSCOPIC EXAMINATION: Twelve (12) glass slides consisting of hematoxylin & eosin stained tissue samples are examined, yielding the following findings:

Heart (myocardium, multiple sections): slight to marked, variable, myocyte hypertrophy; slight, patchy myocardial fibrosis; absence of acute or chronic inflammation.

Lungs (multiple sections): pulmonary congestion; focal intra-alveolar hemorrhage; absence of acute inflammation; minimal anthracotic pigment accumulation.


Liver: minimal lymphocytic infiltration within portal triads; absence of steatosis or fibrosis.

Spleen: moderate congestion.

Kidney: slight cortical and medullary congestion; absence of acute or chronic inflammation; minimal arteriolonephrosclerosis.

Adrenal: medullary congestion.

Pancreas: moderate autolysis; absence of inflammation or fibrosis.



WILLIAMS, Robin M.

C14-173

7

Thyroid: no significant histopathologic changes.

Prostate: benign, nodular hyperplasia; no evidence of prostate carcinoma.


Brain, brainstem, and cerebellum: absence of acute inflammation or tumor; glass slides, tissue blocks and formalin fixed tissue samples submitted for formal consultation (see separate neuropathology report)



Joseph I. Cohen, M.D.
Chief Forensic Pathologist

10-31-14

Date






UNIVERSITY OF CALIFORNIA SAN FRANCISCO
DEPARTMENT OF PATHOLOGY
505 PARNASSUS AVE., M-551
SAN FRANCISCO, CA 94143-0102
TEL: (415) 353-1613 FAX: (415) 353-1612

SURGICAL PATHOLOGY REPORT

Patient Name: DOE, JOHN	Visit #: [REDACTED]	Accession #: S14- [REDACTED]
Med. Rec. #: [REDACTED]	Sex: Male	Service Date: 10/20/2014
DOB: 7/21/1951 (Age: 63)	Location: PA1	Received: 10/20/2014
Soc. Sec. #: [REDACTED]		Client: Marin County Coron
Physician(s): DOCTOR PROVIDER		
Copy To: Joseph I. Cohen, MD		
Forensic Pathologist		
United Forensic Services, P.C.		
448 Ignacio Blvd, Suite 325		
Novato, CA 94949		



FINAL PATHOLOGIC DIAGNOSIS

Review of outside slides from Marin County Coroner, San Rafael, CA:

Brain, forensic evaluation (CR14-173, N/A):

1. Diffuse Lewy body dementia, with prominent alpha synuclein proteinopathy involving neurons in the substantia nigra, ventral tegmental area, occipital cortex, insular cortex, temporal cortex, putamen, and amygdala; see comments in the Microscopic Description section.
2. Tauopathy, affecting neurons in the anterior hippocampus, temporal cortex, cerebral cortex and subcortical white matter of unspecified location, and dorsal raphe nucleus in midbrain.
3. Diffuse astrogliosis involving subcortical white matter, cerebellar white matter, and tementum of the midbrain.
4. Amyloid angiopathy.
5. Extravasation of blood in the perivascular space and adjacent brain parenchyma, midbrain.

COMMENT:

H&E-stained sections for blocks A, B, I, J, K, and L were received for consultation, along with fragments of formalin-fixed brain tissue. Portions of the formalin-fixed tissue with identifiable anatomic structures

DOE, JOHN (MR # [REDACTED])**S14-[REDACTED]**

or with gross findings were submitted for processing at UCSF (cassettes M through S). A panel of immunohistochemical stains was performed on all of the sections, and the findings are summarized in the comments that follow the Microscopic Description. Sections of the visceral organs (cassettes C through G) were not reviewed.

Microscopic Description

A. Brain, occipital cortex:

1. Diffuse Lewy body dementia, with abnormal alpha-synuclein-positive protein aggregates in neurons of layers 5 and 6 of the cerebral cortex.
2. Astrogliosis, subcortical white matter.

B. Brain, insular cortex and putamen:

1. Diffuse Lewy body dementia, with abnormal alpha-synuclein-positive Lewy body in scattered neurons in the insular cortex and alpha-synuclein-positive Lewy neurites in putamen.
2. Astrogliosis, subcortical white matter.

H. Brain, cortex from unspecified location and cerebellum:

1. Diffuse Lewy body dementia, with scattered alpha-synuclein-positive Lewy neurites and occasional cortical neurons with dense alpha-synuclein-positive Lewy bodies.
2. Tauopathy, with scattered cortical neurons with abnormal accumulation of tau positive protein in neurofibrillary tangles.
3. Astrogliosis, subcortical white matter of cortex and cerebellum.

I: Brain, left substantia nigra:

1. Diffuse Lewy body dementia, with reduced neuronal density in the substantia nigra and ventral tegmental area. Several remaining neurons showing alpha-synuclein and/or ubiquitin positive Lewy bodies and Lewy neurites.
2. Microgliosis involving substantia nigra.
3. Acute hemorrhage in small vessel perivascular white matter.

J: Brain, left substantia nigra:

1. Diffuse Lewy body dementia, with reduced neuronal density in substantia nigra and ventral tegmental area and widespread alpha-synuclein-positive Lewy bodies and neurites involving remaining neurons in substantia nigra, ventral tegmental area and raphe nucleus.
2. Microgliosis and astrogliosis involving substantia nigra.
3. Acute hemorrhage in small vessel perivascular white matter.

K. Brain, right substantia nigra:

1. Diffuse Lewy body dementia, with reduced neuronal density in substantia nigra and ventral tegmental area and widespread alpha-synuclein-positive Lewy bodies and neurites involving remaining neurons in substantia nigra, ventral tegmental area and raphe nucleus.
2. Astrogliosis involving periaqueductal grey matter, substantia nigra, and colliculus.
3. Microgliosis involving substantia nigra.
4. Acute hemorrhage in small vessel perivascular white matter.


L: Brain, right substantia nigra:

1. Diffuse Lewy body dementia, with reduced neuronal density in substantia nigra and ventral tegmental area and widespread alpha-synuclein-positive Lewy bodies and neurites involving remaining neurons in substantia nigra and ventral tegmental area.
2. Microgliosis, substantia nigra.
3. Acute hemorrhage in small vessel perivascular white matter.

M: Brain, fragment of midbrain: Diffuse Lewy body dementia, with alpha-synuclein-positive Lewy neurites and Lewy bodies, involving the ventral tegmental area and periaqueductal grey matter neurons.

N. Brain, anterior hippocampus:

1. Diffuse Lewy body dementia, with abnormal alpha-synuclein-positive Lewy bodies and Lewy neurites,



DOE, JOHN (MR # [REDACTED])**S14-[REDACTED]**

involving the amygdala and anterior hippocampus.

2. Tauopathy, with frequent neurons containing globose or flame-shaped tau positive neurofibrillary tangles.

O: Brain, anterior hippocampus:

1. Diffuse Lewy body dementia, with abnormal alpha-synuclein-positive Lewy bodies and Lewy neurites, involving the amygdala and anterior hippocampus.

2. Tauopathy, with frequent neurons containing globose or flame-shaped tau positive neurofibrillary tangles.

P: Brain, cortex with prominent vessels:

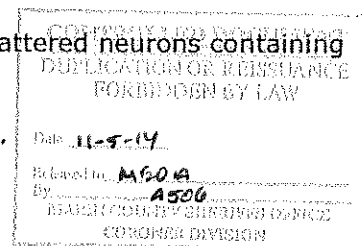
1. Diffuse Lewy body dementia, with scattered neurons containing abnormal alpha-synuclein positive inclusions.

2. Amyloid angiopathy.

Q: Brain, gray matter and subcortical white matter: Scattered cortical neurons with p62 and ubiquitin staining in the cytoplasm.

R: Brain, putamen and internal capsule: Diffuse Lewy body dementia, with scattered neurons containing abnormal alpha-synuclein-positive inclusions.

S: Brain, cerebellum: Scattered p62 positive structures in the molecular layer.



Microscopic Description Comments:

The most prominent features in the submitted H&E-stained sections are the presence of Lewy bodies in the pigmented neurons of the substantia nigra, with a variable degree of loss of the pigmented neurons in both the left and right substantia nigra and the adjacent ventral tegmental area (VTA). Overall, the loss of pigmented substantia nigra and VTA neurons is estimated at 30% to 40%, with most of the remaining neurons showing abnormal cytoplasmic inclusions. The extent of neuron loss in the substantia nigra is consistent with the clinical history of an early disease process. In addition, there are neurons in the temporal cortex and rare neurons in the raphe nucleus (midbrain) showing features of neurofibrillary tangles. In order to further characterize the extent of neurodegenerative features in this case, we performed a series of immunohistochemical stains, and the results are summarized as follows:

Alpha-synuclein immunohistochemistry: The majority of the remaining pigmented neurons in the substantia nigra show prominent alpha-synuclein-positive protein aggregates in the neuronal cytoplasm.

Many of the aggregates show typical features of Lewy bodies and Lewy neurites. The alpha-synuclein proteinopathy can also be identified in neurons in several cortical and subcortical areas, including the visual cortex, insular cortex, temporal cortex, putamen, and other unspecified cortical regions. The feature of alpha-synuclein protein aggregate in cortical neurons are characteristic of what has been described as cortical Lewy bodies, in that they form dense cytoplasmic aggregates rather than the typical Lewy bodies with dense core and halo seen in the midbrain. In addition to the above findings, alpha-synuclein positive Lewy neurites are also identified in the putamen, consistent with targeted innervation of this structure by the nigral dopaminergic neurons. Alpha-synuclein and ubiquitin pathology can also be identified in the ventral tegmental area (VTA), a region between the substantia nigra and the raphe nucleus, in the midbrain. Together, the distribution and the abundance of alpha-synuclein proteinopathy in neocortex, limbic structures and midbrain supports the diagnosis of Diffuse Lewy body dementia (aka Diffuse Lewy body disease).

Tau immunohistochemistry: In the anterior hippocampus and temporal cortex (sections N and O) and in an unspecified cerebral cortex section (section H), we have identified scattered neurons with dense tau positive neurofibrillary tangles. The morphology of tau-positive neurofibrillary tangles ranges from the flame-shaped to the globose features. In addition, the neuropil in these cortical sections also shows short, twisted tau positive neurites in the background. There are occasional glial cells in the subcortical white matter with tau positive processes, some of which resemble "coil bodies" - a feature seen in patients with frontotemporal lobar degeneration (FTLD). However, no definite features of tufted

DOE, JOHN (MR # [REDACTED])**S14-[REDACTED]**

astrocytes or thorny astrocytes are seen. The tauopathy is also identified in rare neurons in the substantia nigra and also in the raphe nucleus, but this is less abundant than the degree of tau pathology identified in the sections of cortex. The presence of tau-positive neurofibrillary tangles has been considered as key diagnostic features of Alzheimer's disease and FTLT.

A-beta amyloid immunohistochemistry: There is no evidence of A-beta amyloid positive plaques in any of the submitted sections. However, there are abundant neurons throughout the cerebral cortex and the midbrain showing prominent A-beta amyloid staining in vesicular structures in the neuronal cytoplasm. This feature has been described as an indicator of cellular stress in neurons. In addition, a single section of cortex from an unspecified location shows dense amyloid staining around small vessels, a feature diagnostic of amyloid angiopathy. The other cortical sections do not show leptomeningeal vessels, so the extent of this finding cannot be accurately determined.

GFAP and CD68 immunohistochemistry: There is diffuse, moderate astrogliosis in the subcortical white matter of the cerebral cortex and cerebellum, and in the tegmentum of the midbrain. In the substantia nigra, there is prominent microgliosis in areas where severe neuronal loss is present. These features are consistent with neurodegeneration related to the Diffuse Lewy body dementia and/or the tau pathology.

p62 and ubiquitin immunohistochemistry: Immunostains for p62 and ubiquitin show overlap with the immunostains for alpha synuclein and tau, and highlight globose cytoplasmic inclusions and/or flame-shaped neurofibrillary tangles in the relevant tissue sections. In addition, several sections show a granular background staining with ubiquitin. Sections of the cerebellum (slide S) and the internal capsule (slide R) show a degree of staining for p62 and/or ubiquitin, without concurrent positive staining for tau or alpha synuclein.

TDP-43 immunohistochemistry: No evidence of TDP-43 proteinopathy in any of the sections examined.

Summary: In conclusion, these neuropathologic findings in this case support the diagnosis of diffuse Lewy body dementia (aka diffuse Lewy body disease or DLBD) using the most recent guidelines established by the National Institute on Aging/Alzheimer's Disease Association (NIA/AA)[1,2], which is characterized pathologically by the presence of alpha-synuclein proteinopathy that affects cerebral cortex, limbic structures and brainstem (including midbrain, pons and medulla oblongata). In contrast to the diffuse alpha-synuclein proteinopathy in DLBD, the alpha-synuclein proteinopathy in Parkinson's disease (PD) is more restricted to brainstem structures [1,2]. Despite the current guidelines, however, given the extensive overlapping of the alpha-synuclein proteinopathy in DLBD and PD and the co-presentation of alpha-synuclein proteinopathy with tau pathology, others have proposed the terminology of Parkinson's Disease Dementia (PDD) to encompass the spectrum of pathology in DLBD and PD [3]. It is important to note that patients with diffuse Lewy body dementia frequently present with Parkinsonian motor symptoms and a constellations of neuropsychiatric manifestations, including depression and hallucination. Clinical correlations with the decedent's neuropsychiatric presentations are strongly recommended.

Another contributing neurodegenerative feature is the tauopathy, which is identified in scattered cortical neurons in the anterior hippocampus, temporal cortex and the dorsal raphe nucleus in midbrain. In addition, there are rare astrocytes with abnormal tau protein aggregates. As mentioned above (in "Tau Immunohistochemistry"), similar features of tauopathy have been described in Alzheimer's disease and in frontotemporal lobar degeneration with tauopathy (FTLD-Tau)[1]. Similar tau protein pathology has also been associated with Parkinson's Disease Dementia [3]. While the significance and contributions of the tau protein pathology in this case remains unclear, it is important to point out that regions affected by the tau protein pathology, including anterior hippocampus, temporal cortex (adjacent amygdala) and dorsal raphe nucleus of midbrain, are important for cognitive functions, mood control and emotion. Hence, it is likely that the presence of tau protein pathology may have contributed to the neuropsychiatric manifestations in the decedent. Correlations with the decedent's clinical presentations are strongly recommended.

Dr. Matthew Wood and Dr. Eric Huang have discussed and communicated the findings with Dr. Joseph

DATE: 11-5-14
 BY: MCDIA
 ASG
 MARSH COUNTY SHERIFF'S OFFICE
 CORONER DIVISION
 FORFEITURE BY LAW

DOE, JOHN (MR # [REDACTED])**S14-[REDACTED]**

Cohen on 10/24/2014 and 10/28/2014.

References:


1. Montine TJ, et al. National Institute on Aging/Alzheimer's Disease Association guidelines for the neuropathologic assessment of Alzheimer's disease: A practical approach. Acta Neuropath 123(1): 1-11, 2012.
2. McKeith IG, et al. Diagnosis and management of dementia with Lewy bodies: third report of the DLB Consortium. Neurology 65: 1836-72, 2005.
3. Irwin DJ, et al. Parkinson's disease dementia: convergence of a-synuclein, tau and amyloid- β pathologies. Nature Rev Neurosci 14: 626-636, 2013.

All controls performed with the immunohistochemical stains reported above reacted appropriately. These immunohistochemical stains were developed and their performance characteristics determined by the UCSF Medical Center Department of Pathology. They have not been cleared or approved by the U. S. Food and Drug Administration. The FDA has determined that such clearance or approval is not necessary. These tests are used for clinical purposes. They should not be regarded as investigational or for research. This laboratory is certified under the Clinical Laboratory Improvement Amendments of 1988 ("CLIA") as qualified to perform high-complexity clinical testing.

Gross Description**- Case: CR14-173**

- Institution: Marin County Coroner.
- City, State: San Rafael, CA.
- Pathologist: Joseph I. Cohen, M.D.
- Procedure Date: N/A.
- Cover Letter Date: N/A.
- Slides received: 12.
- Blocks received: 12.

- One container of formalin with several unoriented fragments of brain tissue, whchiasfdkffjafjd, which upon further examinations revealed features of anterior hippocampus and adjacent temporal cortex and amygdala, and other unspecified regions of cerebral cortex and deep structures.

**Clinical History**

The patient is a 63-year-old man. According to the provided information, the patient developed Parkinsonian signs since approximately 2011. Symptoms included a left arm tremor, and slowing of the left hand movements. The patient was diagnosed with Parkinson's disease in November 2013. Treatment with pramipexole in May 2014 led to some improvement, and levodopa was recently added to his medication regimen. The patient remained physically active until his death in August 2014.

The clinical history is notable for depression, with components of paranoia, compulsiveness, and anxiety. There is a remote history of chronic alcohol and illicit drug abuse. Postmortem toxicology was negative for alcohol or illicit drugs.

Findings on the autopsy examination include cardiac hypertrophy and dilatation. On gross examination of the brain, the right substantia nigra appeared pale in contrast to the left.

Dr. Eric Huang, UCSF Division of Neuropathology, is asked to review the brain microscopy for the case by Dr. Joseph Cohen, United Forensic Services P.C.

DOE, JOHN (MR # [REDACTED])

S14-[REDACTED]

Diagnosis based on gross and microscopic examinations. Final diagnosis made by attending pathologist following review of all pathology slides. The attending pathologist has reviewed all dictations and preliminary interpretations performed by any resident involved in the case and performed all necessary edits before signing the final report.

Matthew D. Wood/Pathology Resident

Eric J. Huang/Pathologist
Signed: 10/28/2014 14:4

CERTIFIED DOCUMENT
 DUPLICATION OR REPRODUCTION
 FORBIDDEN BY LAW

Date: 10-5-14

Released to: MEDIC
 By: AEOG

LABORATORY SERVICE DIVISION
 CHICAGO POLICE DEPARTMENT

Order Requisition



NMS

LABS

3701 Welsh Rd.
 Willow Grove, PA 19090
 215-657-4900 * 800-522-6671
 Fax: 215-366-1501
 www.nmslabs.com

Accession ID/Req ID: [REDACTED]
 Collection Date: 08/12/2014
 Collection Time: 10:00:00

When you need to know.®

Patient Information		Requesting Location
Williams Robin M	DOB: 07/21/1951 Gender: Male	Darrell Harris [REDACTED] Civic Center - Room 145 San Rafael, CA 94903 Phone: Fax:
Web Portal PID: [REDACTED] Patient ID/Case ID: CR14-173		

Order Information	
Should specimen be returned (addl. charge):	No
Matrix/Source:	Bile, Blood-Femoral, Fluid-Vitreous, Urine-Postmortem
Comments:	

Tests Ordered
8092B - Postmortem Toxicology - Expert, Blood (Forensic) Specimen Condition: POSTMORTEM Can Nms Consume The Sample For Analysis?: YES Can Nms Micro-Aliquot Samples In Cases With Low Volume?: YES

UNCONTROLLED DOCUMENT
 DUPLICATION OR REISSUANCE
 FORBIDDEN BY LAW

Date: 11-5-14
 Released to: [REDACTED]
 By: [REDACTED]
 CLAYTON COUNTY SHERIFFS OFFICE
 CORONER DIVISION

Chain of Custody (Use only if necessary)			
Purpose of Transfer	Released by: Sign/Print Name	Received by: Sign/Print Name	Date

Note: NMS does not provide Medicare, Medicaid, or any other third party billing services.



NMS Labs
 3701 Walsh Road, PO Box 433A, Willow Grove, PA 19090-0437
 Phone: (215) 657-4900 Fax: (215) 657-2972
 e-mail: nms@nmslabs.com
 Robert A. Middleberg, PhD, DABFT, DABCC, Laboratory Director

CONFIDENTIAL

August 28, 2014

TO: 10345
 Marin County Sheriff Coroner
 Attn: Sgt. Keith Boyd
 1600 Los Gatos Drive, Suite 205
 San Rafael, CA 94903


TOXICOLOGY REPORT OF: X,X
 NMS Workorder No.: [REDACTED]
 NMS Control No.: [REDACTED]
 Client ID No.: CR14-173

SPECIMENS: Three (3) labeled gray top tubes (one containing ~ 10.5 mL of femoral blood, one containing ~ 10 mL of femoral blood, and one containing ~ 9 mL of femoral blood); and four (4) labeled red top tubes (one containing ~ 2 mL of femoral blood [leaked in transit], one containing ~ 11 mL of urine, one containing ~ 4 mL of vitreous, and one containing ~ 8 mL of bile [leaked in transit]) were received on 08/14/2014.

EXAMINATION: Analysis Requested – 8092B – Postmortem Toxicology – Expert, Blood (Forensic)

FINDINGS:Blood

MIRTAZAPINE (by GC/MS and GC)	40 ng/mL
DESMETHYLMIRTAZAPINE (by GC/MS)	Positive
CAFFEINE (by GC/MS)	Positive
THEOBROMINE (by GC/MS)	Positive



Other than the above findings, examination of the specimens submitted did not reveal any positive findings of toxicological significance by procedures outlined in the Analysis Summary.

COMMENTS:

- Mirtazapine has been used clinically as an antidepressant since 1994. It is available as tablets containing 15, 30, and 45 mg. Daily doses for adults are usually in the range of 15 to 45 mg. The oral bioavailability of the drug is approximately 50%. It is well distributed and metabolized to several weakly active products, including desmethylmirtazapine.

Steady-state plasma levels following a daily regimen:

15 mg/day: 27 - 51 ng/mL (peak); 4.3 - 12 ng/mL (trough)
 30 mg/day: 56 - 104 ng/mL (peak); 11 - 25 ng/mL (trough)
 45 mg/day: 84 - 142 ng/mL (peak); 17 - 39 ng/mL (trough)
 60 mg/day: 117 - 199 ng/mL (peak); 25 - 52 ng/mL (trough)
 75 mg/day: 137 - 225 ng/mL (peak); 28 - 64 ng/mL (trough)

In one case involving an apparent overdose with Mirtazapine, a postmortem blood concentration of 2700 ng/mL was reported.

CONFIDENTIAL

NMS Workorder No:

NMS Control No:

Client ID No:

Page 2 of 3

CR14-173

2. Caffeine is a xanthine-derived central nervous system stimulant. It also produces diuresis and cardiac and respiratory stimulation. It can be readily found in such items as coffee, tea, soft drinks and chocolate. As a reference, a typical cup of coffee or tea contains between 40 to 100 mg caffeine.

Following the oral ingestion of 120 and 300 mg of caffeine, reported peak plasma concentrations of the drug averaged 3.0 mcg/mL (range, 2.0 - 4.0 mcg/mL) and 7.9 mcg/mL (range, 6.0 - 9.0 mcg/mL), respectively. A single oral dose of 500 mg produced a reported peak plasma concentration of 14 mcg/mL after 30 minutes. Reported concentrations of caffeine in caffeine-related fatalities averaged 183 mcg/mL (range, 79 - 344 mcg/mL).

The reported qualitative result for this substance is indicative of a finding commonly seen following typical use and is usually not toxicologically significant.

3. Theobromine is a methylxanthine alkaloid found in tea and cocoa. It is also a metabolite of caffeine. Theobromine has the general properties of the xanthines, including diuresis and smooth muscle stimulation.

Respectfully,



Lee M. Blum, Ph.D., DABFT
Forensic Toxicologist

This analysis was performed under chain of custody. The chain of custody documentation is on file at NMS Labs.

Unless alternate arrangement are made by you, the remainder of the submitted specimens will be discarded two (2) years from the date of this report; and generated data will be discarded five (5) years from the date the analyses were performed.

ANALYSIS SUMMARY and REPORTING LIMITS:

All of the following tests were performed for this case. For each test, the compounds listed were included in the scope. Please refer to the Findings section of the report for those compounds that were identified as being present.

Acocde 8092B - Postmortem Toxicology - Expert, Blood (Forensic) - Femoral Blood

-Analysis by Headspace Gas Chromatography (GC) for:


<u>Compound</u>	<u>Rpt. Limit</u>	<u>Compound</u>	<u>Rpt. Limit</u>
Acetone	5.0 mg/dL	Isopropanol	5.0 mg/dL
Ethanol	10 mg/dL	Methanol	5.0 mg/dL

-Analysis by Enzyme-Linked Immunosorbent Assay (ELISA) for:

<u>Compound</u>	<u>Rpt. Limit</u>	<u>Compound</u>	<u>Rpt. Limit</u>
Benzodiazepines	100 ng/mL	Opiates	20 ng/mL
Cannabinoids	10 ng/mL	Oxycodone	10 ng/mL
Cocaine / Metabolites	20 ng/mL	Salicylates	120 mcg/mL

-Analysis by Enzyme-Linked Immunosorbent Assay (ELISA) for:

<u>Compound</u>	<u>Rpt. Limit</u>
Buprenorphine / Metabolite	0.50 ng/mL



CONFIDENTIAL

NMS Workorder No: [REDACTED]
NMS Control No:
Client ID No: CR14-173
Page 3 of 3

-Analysis by Gas Chromatography/Mass Spectrometry (GC/MS) for:
The following is a general list of compound classes included in the Gas Chromatographic screen. The detection of any particular compound is concentration dependent. Please note that not all known compounds included in each specified class or heading are included. Some specific compounds outside these classes are also included. For a detailed list of all compounds and reporting limits included in this screen, please contact NMS Labs.

Amphetamines, Analgesics (opioid and non-opioid), Anorectics, Anesthetics, Antiarrhythmics, Anticholinergic Agents, Anticoagulant Agents, Anticonvulsant Agents, Antidepressants, Anticemetic Agents, Antifungal Agents, Antihistamines, Antihypertensive Agents, Antiparkinsonian Agents, Antipsychotic Agents, Antitussive Agents, Antiviral Agents, Anxiolytics (Benzodiazepine and others), Calcium Channel Blocking Agents, Cardiovascular Agents (non digitalis), Hallucinogens, Hypnotics (Barbiturates, Non-Benzodiazepine Hypnotics, and others), Local Anesthetics Agents, Muscle Relaxants, Non-Steroidal Anti Inflammatory Agents (excluding Salicylate) and Stimulants (Amphetamine-like and others).

Acocde 52147B Antidepressants / Antihistamines - Confirmation Panel 1, Blood (Forensic) - Femoral Blood

-Analysis by Gas Chromatography (GC) for:

<u>Compound</u>	<u>Rpt. Limit</u>
Mirtazapine	5.0 ng/mL

Acocde 5435B Quinine/Quinidine Confirmation, Blood (Forensic) - Femoral Blood

-Analysis by High Performance Liquid Chromatography/Tandem Mass Spectrometry (LC-MS/MS) for:

<u>Compound</u>	<u>Rpt. Limit</u>
Quinine	100 ng/mL
Quinidine	100 ng/mL

***** END OF REPORT *****

CONFIDENTIAL DOCUMENT
 EVIDENCE FOR PROSECUTION
 FORWARDED BY LAW

Date: 11-5-14
 Released to: M401A
 By: [Signature]
 WASH COUNTY CORONER OFFICE
 CORONER DIVISION

Order Requisition



NMS

LABS

3701 Welsh Rd.
 Willow Grove, PA 19090
 215-657-4900 * 800-522-6671
 Fax: 215-366-1501
 www.nmslabs.com

Accession ID/Req ID: [REDACTED]
 Collection Date: 08/12/2014
 Collection Time: 10:00:00

When you need to know.*

Patient Information		Requesting Location
Williams Robin M	DOB: 07/21/1951 Gender: Male	[REDACTED] D.Harris-MarinCountySheriffCoroner 1600 Los Gamos Drive Suite 205 San Rafael, CA 94903 Phone: Fax:
Web Portal PID: [REDACTED] Patient ID/Case ID: CR14-173		

Order Information	
Should specimen be returned (addl. charge):	No
Matrix/Source:	Bile,Blood-Femoral,Fluid-Vitreous,Serum,Urine-Postmortem
Comments:	Expert tox already completed. We are sending a new serum sample with this shipment for Sinemet testing. See Dr. J. Cohen's included note regarding Sinemet test on hemolized serum sample

Tests Ordered	
8092B - Postmortem Toxicology - Expert, Blood (Forensic)	Specimen Condition: POSTMORTEM Can Nms Consume The Sample For Analysis?: YES Can Nms Micro-Aliquot Samples In Cases With Low Volume?: YES
4205SP - Sinemet®, Serum/Plasma	

*Serum
 SENT 9.11.14
 K.2*

COPIES OF THIS DOCUMENT
 REPRODUCTION OR MISUSE
 FORBIDDEN BY LAW

Date: 11-5-14
 Released to: M201A
 By: ASEV
 MARIN COUNTY SHERIFFS OFFICE
 CORONER DIVISION

Chain of Custody (Use only if necessary)			
Purpose of Transfer	Released by: Sign/Print Name	Received by: Sign/Print Name	Date

Note: NMS does not provide Medicare, Medicaid, or any other third party billing services.



NMS Labs
 3701 Welsh Road, PO Box 433A, Willow Grove, PA 19090-0437
 Phone: (215) 657-4900 Fax: (215) 657-2972
 e-mail: nms@nmslabs.com
 Robert A. Middleberg, PhD, DABFT, DABCC, Laboratory Director

CONFIDENTIAL

September 19, 2014

TO: 10345
 Marin County Sheriff Coroner
 Attn: Sgt. Keith Boyd
 1600 Los Gatos Drive, Suite 205
 San Rafael, CA 94903

SUPPLEMENTAL TOXICOLOGY REPORT OF:

X,X

NMS Workorder No.:

NMS Control No.:

Client ID No.:


CRI14-173

SPECIMENS: Three (3) labeled gray top tubes (one containing ~ 10.5 mL of femoral blood, one containing ~ 10 mL of femoral blood, and one containing ~ 9 mL of femoral blood); and four (4) labeled red top tubes (one containing ~ 2 mL of femoral blood [leaked in transit], one containing ~ 11 mL of urine, one containing ~ 4 mL of vitreous, and one containing ~ 8 mL of bile [leaked in transit]) were received on 08/14/2014. One (1) labeled blue vial containing ~ 3.5 mL of "plasma sample, centrifuged and separated from hemolyzed postmortem femoral blood" was received on 09/12/2014.

EXAMINATION: Analysis Requested – 8092B – Postmortem Toxicology – Expert, Blood (Forensic)
 7719SA – Special Request for Carbidopa/Levodopa (Sinemet®)

FINDINGS:Blood

MIRTAZAPINE (by GC/MS and GC)	40 ng/mL
DESMETHYLMIRTAZAPINE (by GC/MS)	Positive
CAFFEINE (by GC/MS)	Positive
THEOBROMINE (by GC/MS)	Positive
LEVODOPA (by HPLC)	Positive (approximately 0.31 mcg/mL)
CARBIDOPA (by HPLC)	Not Reported – Unable to identify due to the presence of a specimen specific matrix issue.



Other than the above findings, examination of the specimens submitted did not reveal any positive findings of toxicological significance by procedures outlined in the Analysis Summary.

COMMENTS:

- Mirtazapine has been used clinically as an antidepressant since 1994. It is available as tablets containing 15, 30, and 45 mg. Daily doses for adults are usually in the range of 15 to 45 mg. The oral bioavailability of the drug is approximately 50%. It is well distributed and metabolized to several weakly active products, including desmethylmirtazapine.

CONFIDENTIAL

NMS Workorder No: [REDACTED]
 NMS Control No: [REDACTED]
 Client ID No: CR14-173
 Page 2 of 3

Steady-state plasma levels following a daily regimen:

15 mg/day: 27 - 51 ng/mL (peak); 4.3 - 12 ng/mL (trough)
 30 mg/day: 56 - 104 ng/mL (peak); 11 - 25 ng/mL (trough)
 45 mg/day: 84 - 142 ng/mL (peak); 17 - 39 ng/mL (trough)
 60 mg/day: 117 - 199 ng/mL (peak); 25 - 52 ng/mL (trough)
 75 mg/day: 137 - 225 ng/mL (peak); 28 - 64 ng/mL (trough)

In one case involving an apparent overdose with Mirtazapine, a postmortem blood concentration of 2700 ng/mL was reported.

2. Caffeine is a xanthine-derived central nervous system stimulant. It also produces diuresis and cardiac and respiratory stimulation. It can be readily found in such items as coffee, tea, soft drinks and chocolate. As a reference, a typical cup of coffee or tea contains between 40 to 100 mg caffeine.

Following the oral ingestion of 120 and 300 mg of caffeine, reported peak plasma concentrations of the drug averaged 3.0 mcg/mL (range, 2.0 - 4.0 mcg/mL) and 7.9 mcg/mL (range, 6.0 - 9.0 mcg/mL), respectively. A single oral dose of 500 mg produced a reported peak plasma concentration of 14 mcg/mL after 30 minutes. Reported concentrations of caffeine in caffeine-related fatalities averaged 183 mcg/mL (range, 79 - 344 mcg/mL).

The reported qualitative result for this substance is indicative of a finding commonly seen following typical use and is usually not toxicologically significant.

3. Theobromine is a methylxanthine alkaloid found in tea and cocoa. It is also a metabolite of caffeine. Theobromine has the general properties of the xanthines, including diuresis and smooth muscle stimulation.
4. Sinemet® is employed as an antiparkinson agent. Following a single oral dose of 100 mg levodopa and 25 mg carbidopa (conventional Sinemet® tablet) concentrations are approximately 0.3 mcg levodopa/mL and 0.05 mcg carbidopa/mL plasma at one hour post dose. The average steady-state trough plasma levels in elderly patients following a regimen of Sinemet® CR (50 mg carbidopa and 200 mg levodopa sustained release tablets) 3 times daily is 0.16 mcg levodopa/mL and 0.07 mcg carbidopa/mL.

The reported concentrations for these substances may not be a true reflection of the analyte levels at and around the time of death due to known instabilities of these substances.

Respectfully,



Lee M. Blum, Ph.D., DABFT
 Forensic Toxicologist

CONFIDENTIAL DOCUMENT DUPLICATION OR REISSUANCE FORBIDDEN BY LAW	
Date	11-8-14
Referred to	ADD
By	MEO/10
STARCH COUNTY CLERK/DEPUTY CLERK CRIMINAL DIVISION	

This analysis was performed under chain of custody. The chain of custody documentation is on file at NMS Labs.

Unless alternate arrangement are made by you, the remainder of the submitted specimens will be discarded two (2) years from the date of this report; and generated data will be discarded five (5) years from the date the analyses were performed.

ANALYSIS SUMMARY and REPORTING LIMITS:

All of the following tests were performed for this case. For each test, the compounds listed were included in the scope. Please refer to the Findings section of the report for those compounds that were identified as being present.

CONFIDENTIAL

NMS Workorder No:
 NMS Control No:
 Client ID No:
 Page 3 of 3

CR14-173

Acode 8092B – Postmortem Toxicology – Expert, Blood (Forensic) – Femoral Blood

-Analysis by Headspace Gas Chromatography (GC) for:

<u>Compound</u>	<u>Rpt. Limit</u>	<u>Compound</u>	<u>Rpt. Limit</u>
Acetone	5.0 mg/dL	Isopropanol	5.0 mg/dL
Ethanol	10 mg/dL	Methanol	5.0 mg/dL

-Analysis by Enzyme-Linked Immunosorbent Assay (ELISA) for:

<u>Compound</u>	<u>Rpt. Limit</u>	<u>Compound</u>	<u>Rpt. Limit</u>
Benzodiazepines	100 ng/mL	Opiates	20 ng/mL
Cannabinoids	10 ng/mL	Oxycodone	10 ng/mL
Cocaine / Metabolites	20 ng/mL	Salicylates	120 mcg/mL

-Analysis by Enzyme-Linked Immunosorbent Assay (ELISA) for:

<u>Compound</u>	<u>Rpt. Limit</u>
Buprenorphine / Metabolite	0.50 ng/mL

-Analysis by Gas Chromatography/Mass Spectrometry (GC/MS) for:

The following is a general list of compound classes included in the Gas Chromatographic screen. The detection of any particular compound is concentration dependent. Please note that not all known compounds included in each specified class or heading are included. Some specific compounds outside these classes are also included. For a detailed list of all compounds and reporting limits included in this screen, please contact NMS Labs.

Amphetamines, Analgesics (opioid and non-opioid), Anorectics, Anesthetics, Antiarrhythmics, Anticholinergic Agents, Anticoagulant Agents, Anticonvulsant Agents, Antidepressants, Antiemetic Agents, Antifungal Agents, Antihistamines, Antihypertensive Agents, Antiparkinsonian Agents, Antipsychotic Agents, Antitussive Agents, Antiviral Agents, Anxiolytics (Benzodiazepine and others), Calcium Channel Blocking Agents, Cardiovascular Agents (non digitalis), Hallucinogens, Hypnosedatives (Barbiturates, Non-Benzodiazepine Hypnotics, and others), Local Anesthetics Agents, Muscle Relaxants, Non-Steroidal Anti Inflammatory Agents (excluding Salicylate) and Stimulants (Amphetamine-like and others).

Acode 52147B Antidepressants / Antihistamines – Confirmation Panel 1, Blood (Forensic) – Femoral Blood


-Analysis by Gas Chromatography (GC) for:

<u>Compound</u>	<u>Rpt. Limit</u>
Mirtazapine	5.0 ng/mL

Acode 5435B Quinine/Quinidine Confirmation, Blood (Forensic) - Femoral Blood

-Analysis by High Performance Liquid Chromatography/Tandem Mass Spectrometry (LC-MS/MS) for:

<u>Compound</u>	<u>Rpt. Limit</u>
Quinine	100 ng/mL
Quinidine	100 ng/mL



Acode 7719SA – Special Request for Carbidopa/Levodopa (Sinemet®) – Femoral “Plasma”

-Analysis by High Performance Liquid Chromatography (HPLC) for:

<u>Compound</u>	<u>Rpt. Limit</u>
Levodopa	0.05 mcg/mL
Carbidopa	Not Reported

***** END OF REPORT *****